

The Continuing Challenge of Artifacts in the EEG

Donald W. Klass, M.D.

Department of Neurology
Mayo Clinic and Mayo Foundation
Rochester, Minnesota 55905

ABSTRACT. *From the very inception of EEG, the distinction between artifactual and cerebral electrical activity has been crucial. Dealing with artifacts effectively is an essential function of the EEG technologist and continues to be challenging. This review includes examples of common artifacts in unfamiliar guises, uncommon artifacts with identifiable characteristics, and some newer artifacts engendered by changing technology.*

KEY WORDS. *Artifacts, EEG.*

INTRODUCTION

According to the glossary of the International Federation of Clinical Neurophysiology (IFCN), the term *artifact* is described as "any potential difference due to an extracerebral source, recorded in EEG tracings" and also includes more generally "any modification of the EEG caused by extracerebral factors such as alterations of the media surrounding the brain, instrumental distortion or malfunction, and operational errors." Artifacts, however, may also arise from cerebral activity *indirectly*, as will be illustrated later.

Artifacts continue to be important for a number of reasons. First, they are ubiquitous, present in every EEG tracing. Artifacts, if prominent, may obscure the EEG activity and render the EEG uninterpretable. Artifacts can mimic almost any kind of cerebral electrical activity and lead to serious misinterpretation (Williams et al. 1985). And, finally, artifacts can lead to false conclusions when the EEG is transformed by techniques such as topographic displays or power

spectral analysis unless great care is taken to recognize and exclude artifactual activity from the processed data (Nuwer and Jordan 1987, Coburn and Moreno 1988, Nuwer 1988, Mraz and Sullivan 1994).

Attesting to the importance of artifacts, almost every textbook on EEG contains a full chapter on them, and almost every volume of this journal contains at least one article on the subject. The distinction between artifactual and cerebral electrical activity is crucial for accurate diagnosis and interpretation.

Dealing with artifacts is a never-ending and sometimes Sisyphean task for the technologist. It requires excellent training and considerable experience: first, to recognize that a fault exists, and then, to identify the type, determine the source, and eliminate the artifact if possible. If elimination of the artifact is not possible, the technologist should monitor its occurrence and correlate it with any observable sources of interference (Brittenham 1974, Keeney 1981). Although the technologist is the first line of defense in the battle against artifacts, the final responsibility for differentiating extracerebral from cerebral activity rests with the electroencephalographer, since even the most experienced technologist may overlook an artifact while attending to other technical matters, and, as implied in the IFCN definition, an artifact may even be inadvertently generated by the technologist.

Artifacts may be classified into three main categories: 1) *biologic* (arising from the subject or patient), 2) *technologic* (arising from the electrode-subject interface, electrodes, electrode connections, recording equipment, or display apparatus), and 3) *extrinsic* (such as mains line interference; other equipment connected to the patient; airborne sources, including electromagnetic, radio frequency, and electrostatic signals; and other environmental phenomena) (MacGillivray 1974, Dondey and Gaches 1977, Saunders 1979, Brittenham 1990, Fisch 1991). In general, the subsequent illustrations follow this sequence.

Numerous specialized measures described for artifact rejection and minimization by techniques of data processing (Barlow 1986) will not be considered here. Limitations of space also preclude an encyclopedic catalog of artifacts. The focus of this review is to present examples of common artifacts in unfamiliar guises, uncommon artifacts with identifiable characteristics, and some newer types of artifacts engendered by changing technology.

BIOLOGIC ARTIFACTS

Ocular

Excessive eye movements can be a major nuisance and can obscure cerebral activity arising from the frontal lobes. The technologist can often reduce the artifact by holding the eyelids closed (if the patient is not wearing contact lenses)

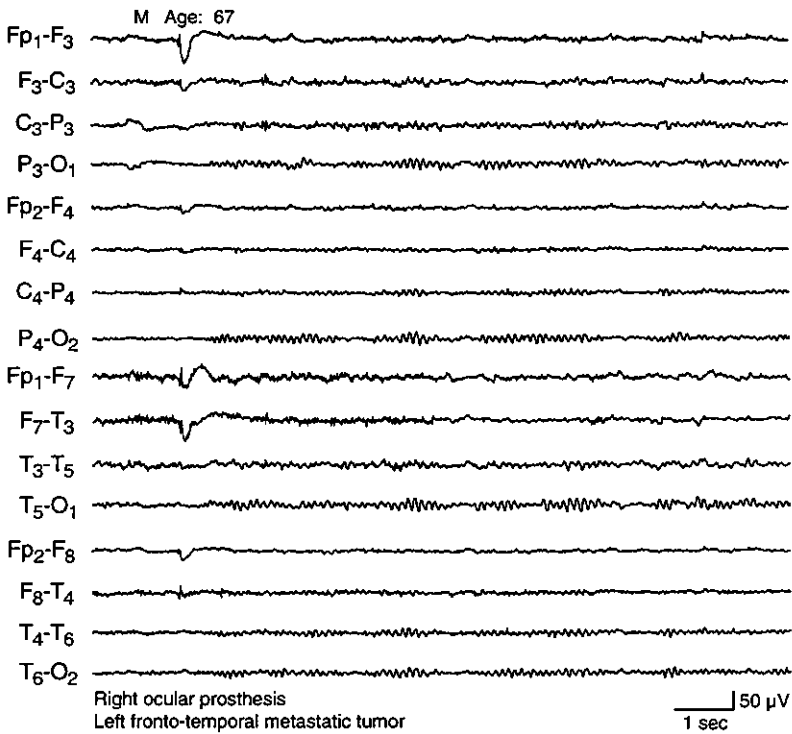


FIG. 1. Asymmetrical eye movements due to absence of right eye are to be differentiated from left frontotemporal delta activity (best seen in channels 9 to 11) resulting from a brain tumor. In the first second of the tracing, there is also an electrode artifact in P3.

and can provide useful monitoring by indicating in the recording when movements of the eyes are palpable. If a distinction between artifact and slow waves of cerebral origin is still in doubt, a definitive solution can be reached by simultaneous recording with supraorbital and infraorbital facial leads connected to a common distant reference, since activity of cerebral origin, even if it extends into the facial leads, is in phase, whereas eye movements are out of phase in these derivations (Tyner et al. 1983, Sullivan 1993).

The technologist should also realize the importance of recognizing and noting a cause for asymmetrical eye movements (Shaffer 1970), either unilateral enucleation of the globe or restricted movements of the globe, to help the electroencephalographer distinguish between unilateral slow waves resulting from eye movement and delta activity of cerebral origin (Figure 1). The slow eye movements (SEMs) that form such an important indicator of drowsiness are usually

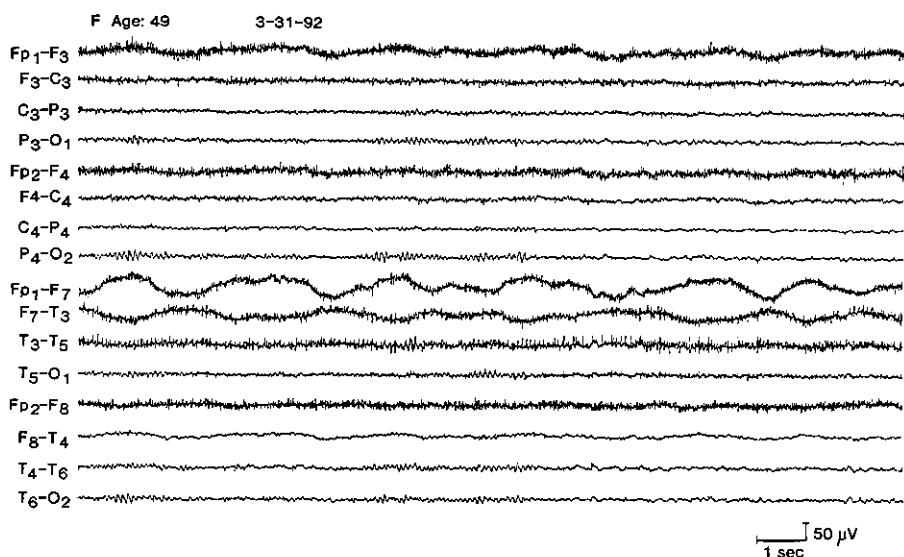


Fig. 2. Asymmetrical slow eye movements of drowsiness (F7, F8) in patient with normal eyes, not to be mistaken for focal delta activity in F7.

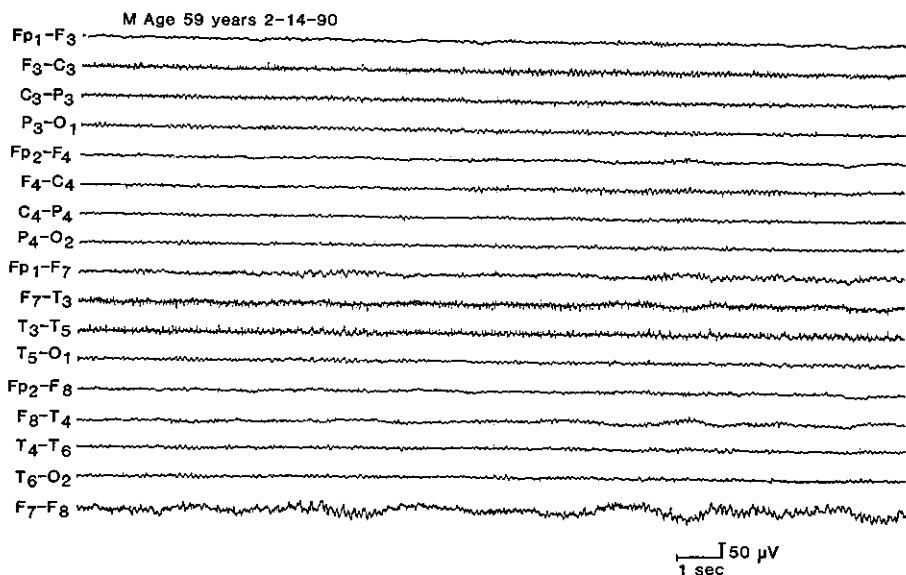


FIG. 3. Accentuation of slow eye movements in interhemispheric derivation (F7-F8).

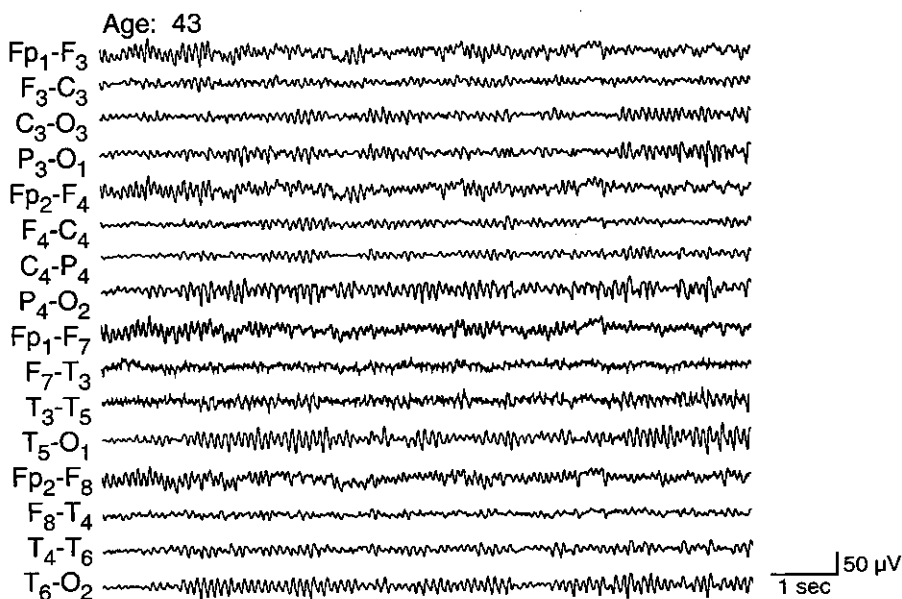


FIG. 4. Eyelid flutter of alpha frequency producing artifacts in Fp1 and Fp2.

symmetrical on the two sides (Blume and Kaibara 1995) but can be asymmetrical without ocular disease (Figure 2). They appear mainly in F7 and F8 with either bipolar or referential recording and are out of phase on the two sides. If there is doubt about whether a particular type of EEG activity is pathologic or a normal drowsy variant, monitoring of drowsiness with an interhemispheric derivation of F7-F8 can be helpful. Such a derivation doubles the potential difference and pen excursion, since the SEMs are usually conjugate movements (Figure 3).

More rapid bifrontal deflections can be produced by eyelid flutter in a tense and anxious patient and need to be differentiated from a pathologic bifrontal rhythm of alpha frequency (Figure 4). Eyelid flutter can usually be interrupted by having the patient open the eyes and fixate gaze. Rapid irregular deflections can also be caused by a mischievous subject producing voluntary nystagmus (Figure 5). These are but two examples of the need for careful observation of the patient.

The typical electrical field distribution of normal eye blinks consists of in-phase decreasing voltage with increasing distance from the eyes. Recognition of an atypical distribution can be a helpful tipoff to inadvertent interchange of electrode inputs as the cause of a simulated abnormality (Figure 6).

Asymmetrical eye movement artifacts may be associated with a frontal skull

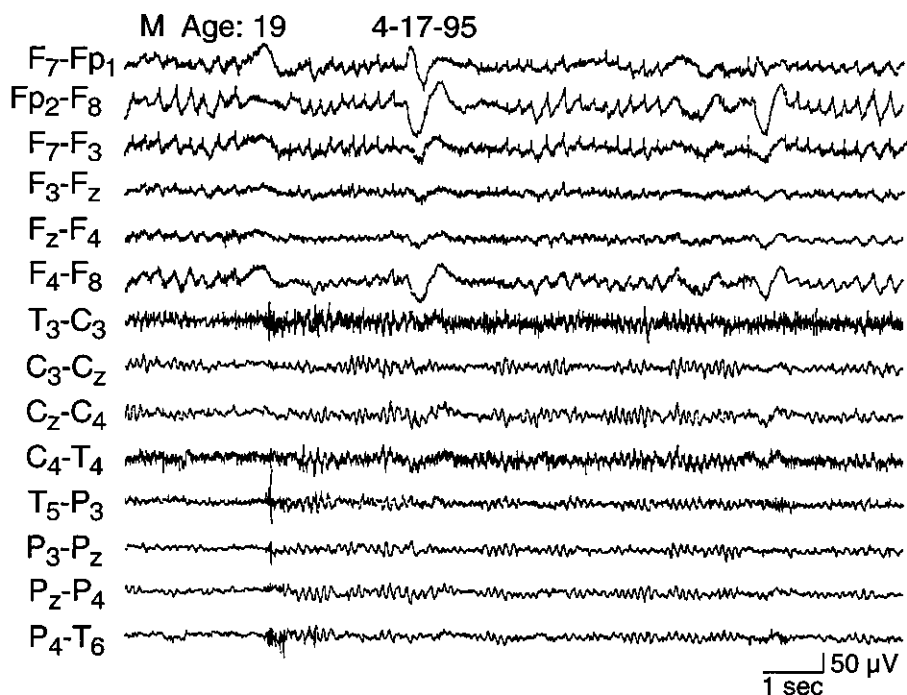


FIG. 5. Repetitive saw-toothed waves (Fp1, Fp2, F7, F8) resulting from voluntary nystagmus.

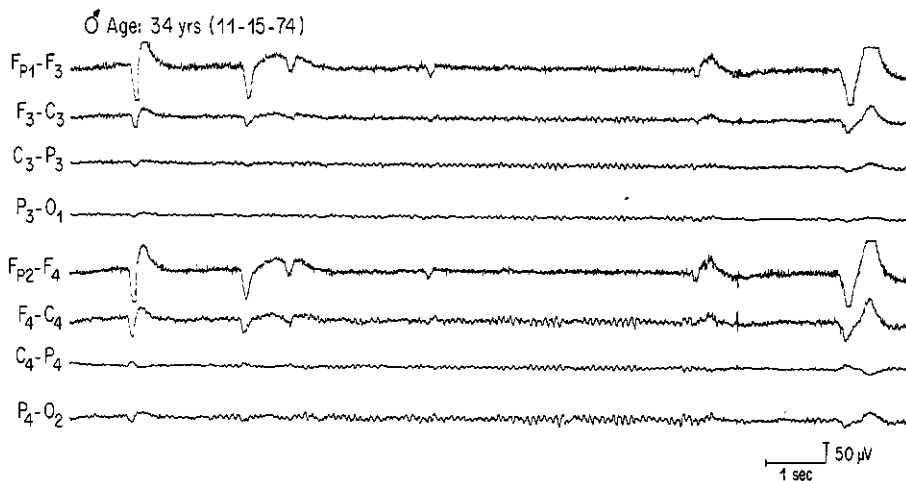


FIG. 6. Electrodes C4 and P4 were inadvertently interchanged in the connecting jack box, producing a spurious asymmetry of EEG activity. Note apparent phase reversal of eye-blink artifacts in P4 compared with the normal distribution on the left side.

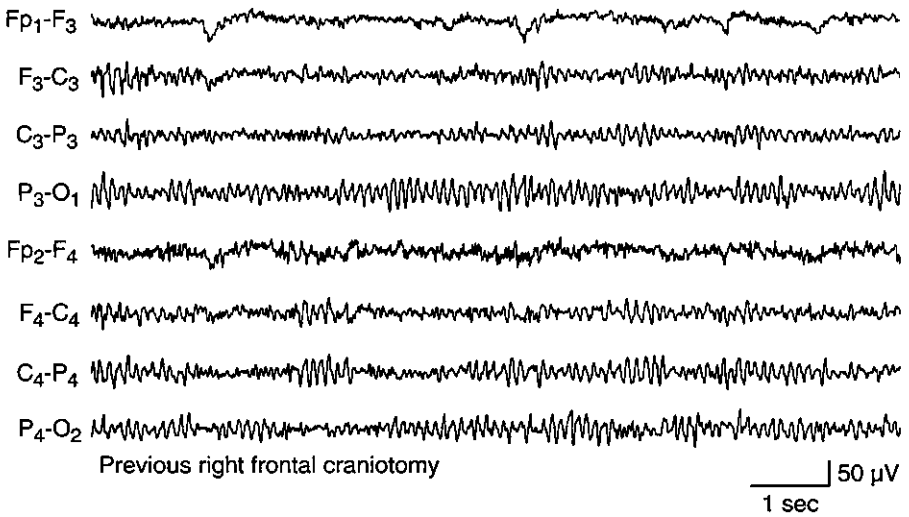


FIG. 7. Lower voltage of eye movement artifact and higher voltage of beta activity in right frontal region (Fp₂) associated with a right frontal skull defect.

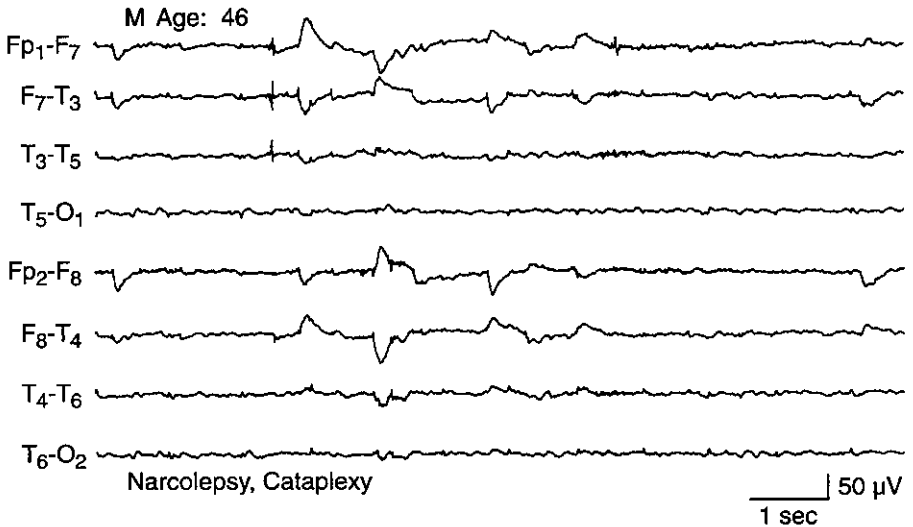


FIG. 8. Typical eye movements during rapid eye movement sleep (best seen in channels 1, 2, 5, and 6).

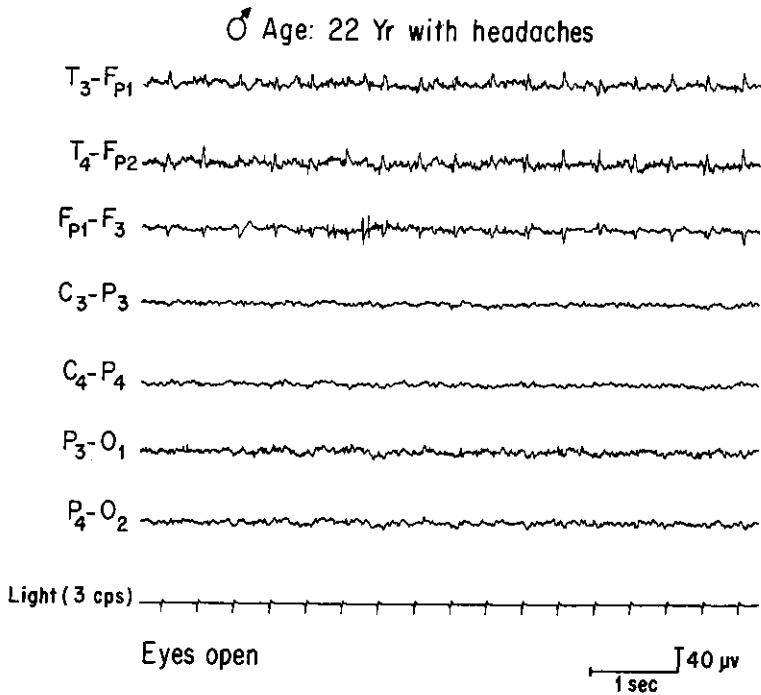


FIG. 9. Electroretinogram recorded from Fp1 and Fp2 (upper 3 channels) in patient who had no retinal disease.

defect. In contrast to the increased voltage of cerebral activity arising beneath a skull defect (breach activity) (Radhakrishnan et al. 1994), the transmitted deflections from eye movement are reduced on the side of a frontal skull defect (Figure 7).

Rapid eye movement (REM) sleep is sometimes encountered during daytime sleep recordings in the EEG laboratory, particularly if the patient had been sleep-deprived beforehand or has narcolepsy (Matsuo and Gaskin 1986). If the sleep recording is being conducted to determine if epileptiform abnormalities can be activated, the technologist should recognize the typical deflections due to REM (Figure 8) and attempt to obtain additional recording during non-REM (NREM) sleep, since REM sleep is not usually a good activator of epileptiform discharges.

Electroretinographic

The electroretinogram (ERG) is typically evident in the prefrontal leads at the high sensitivities needed for recording suspected electrocerebral inactivity,

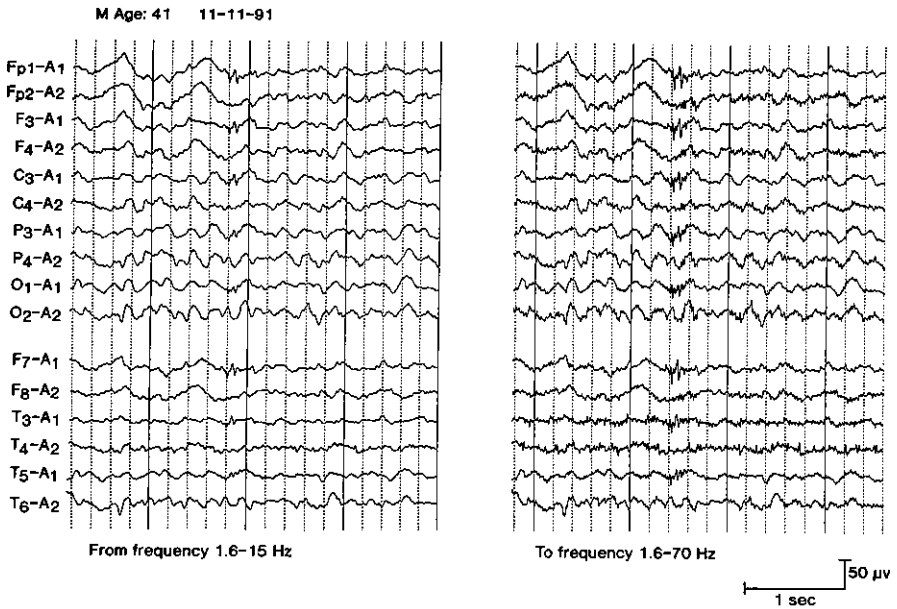


FIG. 10. Digital EEG recording during sleep with high-frequency filter setting of 15 Hz showing a discharge resembling a left frontotemporal sharp wave (segment on left). Reformating of the identical segment with high-frequency filter setting of 70 Hz shows that the discharge is clearly myogenic artifact (segment on right).

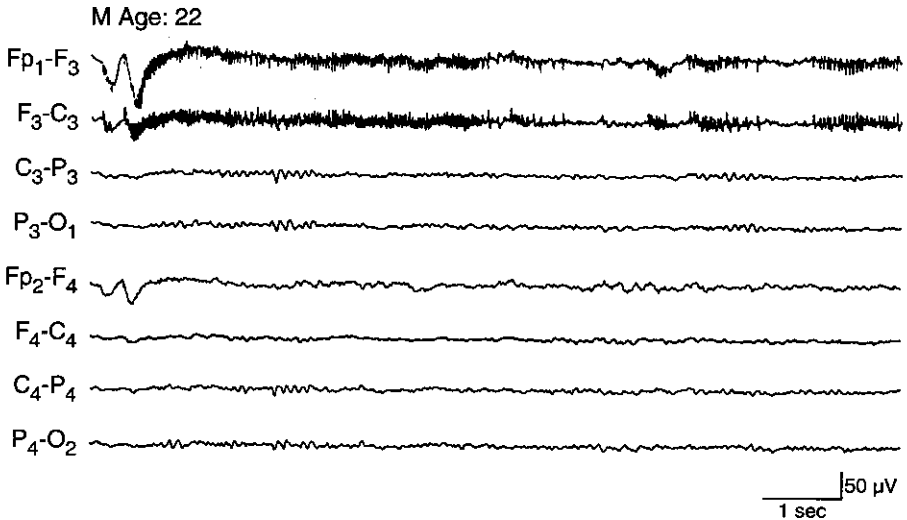


FIG. 11. Left facial synkinesis (channels 1 and 2) following eye closure.

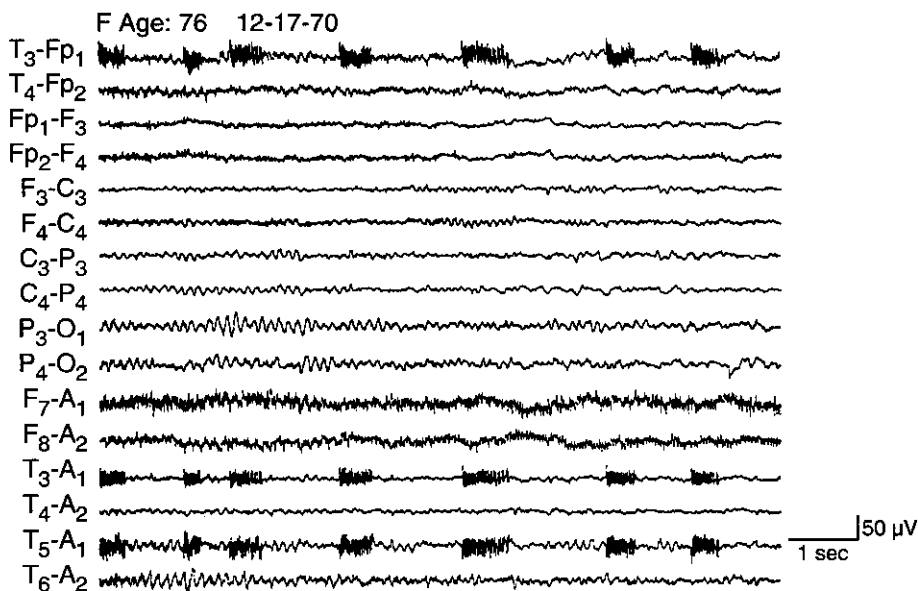


FIG. 12. Quasiperiodic bursts of myogenic potentials in left temporal region (T₃, T₅) due to left-sided facial myokymia.

but the ERG may be recorded in otherwise normal subjects at standard sensitivities (Figure 9). It should not be mistaken for bifrontal spikes of cerebral origin or for a photomyogenic response. The origin of the ERG can be verified by its unilateral disappearance with ipsilateral monocular occlusion (Tyner et al. 1983).

Myogenic

Myogenic artifacts may be difficult to eliminate from recordings of tense and uncooperative patients despite every effort at achieving relaxation. Use of the high frequency filter during the waking record is warranted when searching for slow waves. Use of the high frequency filter should be avoided during a sleep recording: high frequency filtering may blunt myogenic potentials, causing them to more closely resemble spikes of cerebral origin (Figure 10). Unexpected muscle twitches can occur during NREM sleep, especially in children.

Some myogenic artifacts have a characteristic appearance in the EEG and are useful for diagnosis (Westmoreland et al. 1973). Facial synkinesis is associated with a rapid burst of myogenic potentials in the prefrontal region on one side

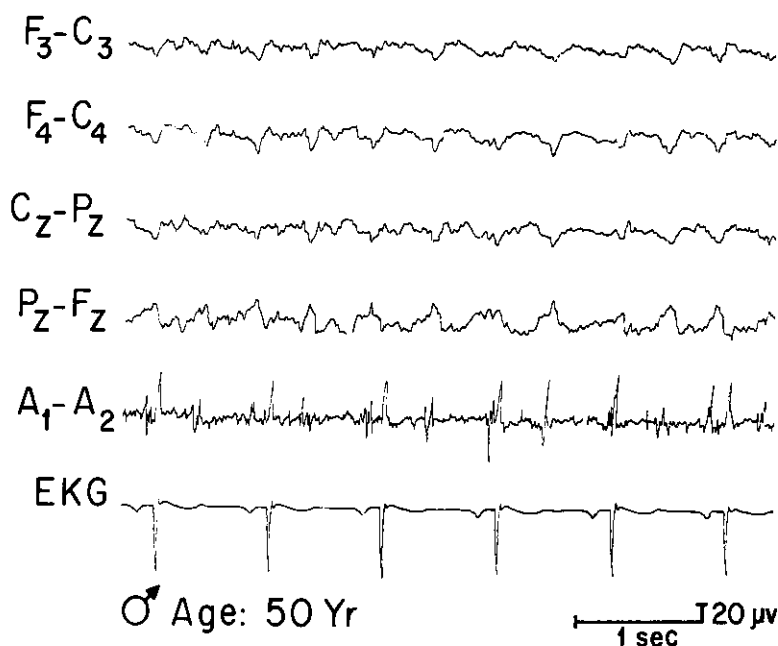


FIG. 13. Periodic nonartifactual waves associated with palatal myoclonus (myogenic artifacts in A1-A2). The QRS complexes of the electrocardiogram are also present in A1-A2, and their timing is identified by the noncephalic electrocardiographic monitor in the lowermost channel (labeled EKG).

following eye blinks or eye closure (Figure 11). It is due to aberrant regeneration of the seventh (facial) cranial nerve after a previous disturbance, such as Bell's palsy.

Facial myokymia is important to recognize, because it is produced by lesions that involve the facial nerve intracranially (Espinosa et al. 1967). It characteristically consists of unilateral short bursts of 30–70 Hz myogenic activity occurring with clear-cut periodicity during wakefulness and during sleep. The bursts do not coincide with respirations. The interval between bursts ranges from about 1 to 5 seconds in different cases. Facial myokymia typically is recorded in Fp1 or Fp2 when the frontalis muscle is involved, but it may be recorded in the temporal leads without visible movement when the vestigial auricularis muscles are involved, since those muscles are also supplied by the facial nerve (Figure 12).

The third useful myogenic artifact to recognize is caused by palatal myo-

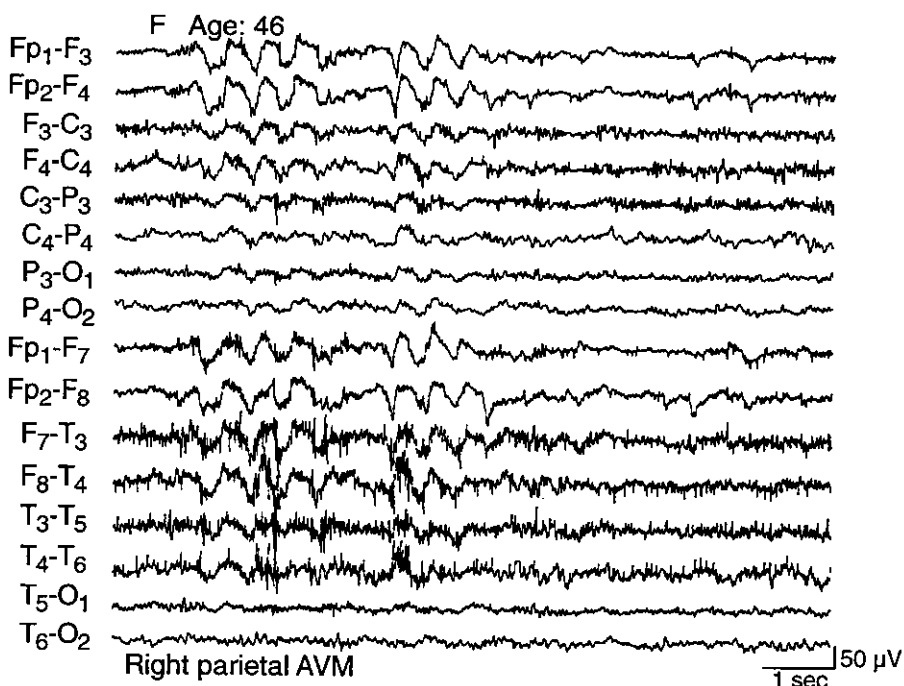


FIG. 14. Prominent glossokinetic potentials obscuring the focal polymorphic delta activity (seen predominantly in C4-P4 and T4-T6), which is evident in the last 5 seconds of the tracing, when the glossokinetic potentials are no longer present. The focal delta abnormality was associated with a right parietal arteriovenous malformation.

clonus. It also has a characteristic periodicity at rates usually of 60–120 beats/min in different patients but consists of brief myogenic contractions that need to be distinguished from the electrocardiogram (ECG) (Franklin 1972) (Figure 13). The patient is often unaware of the movements, and the condition is sometimes first detected in the EEG. The artifact from palatal myoclonus is visible almost exclusively in recordings with ear lead derivations and is most evident in an interear lead derivation (A1-A2). It is caused by intracranial disorders involving brainstem-cerebellar circuits (the dentato-olivary pathway). As first pointed out by Hertzler et al. (1970) and later by Westmoreland et al. (1973) and Jordan et al. (1977), in some patients each myogenic contraction may be followed by an evoked cerebral response in the region of the vertex. Monitoring with an A1-A2 derivation establishes the relationship between the myogenic artifact and this sagittal or parasagittal activity and precludes misinterpretation of the cerebral potentials as periodic epileptiform sharp waves (Figure 13).

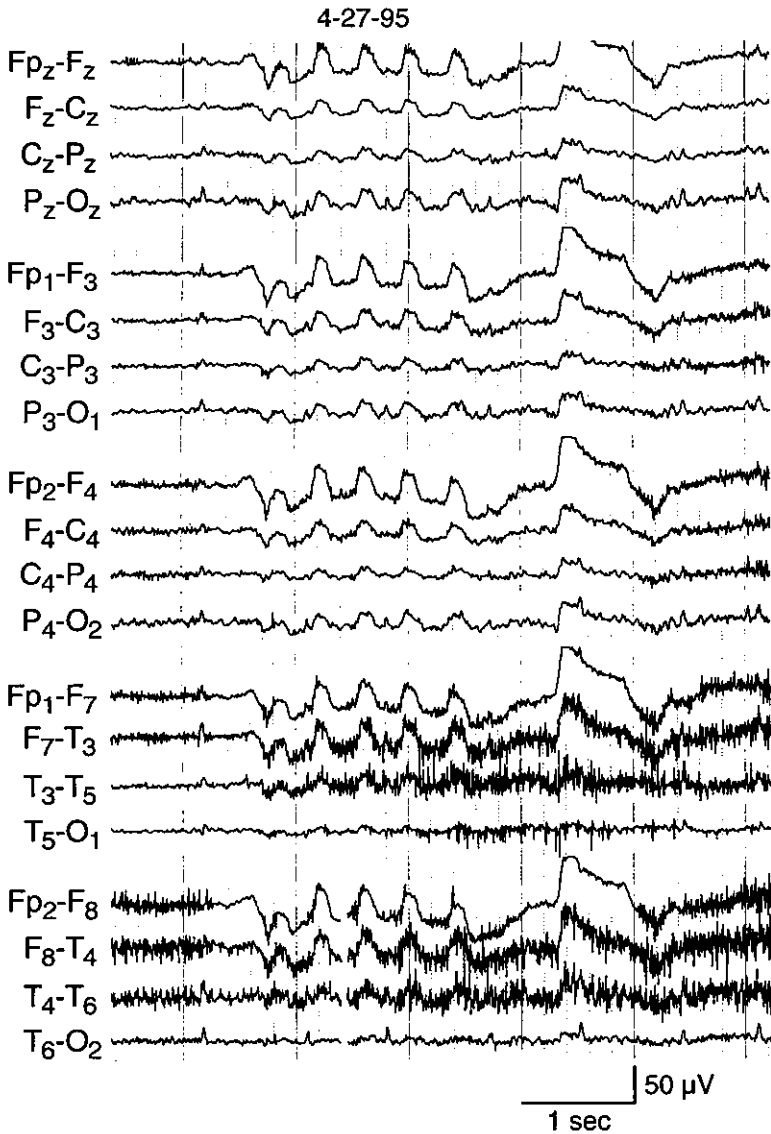


FIG. 15. Prominent glossokinetic potentials resembling frontal intermittent rhythmic delta activity.

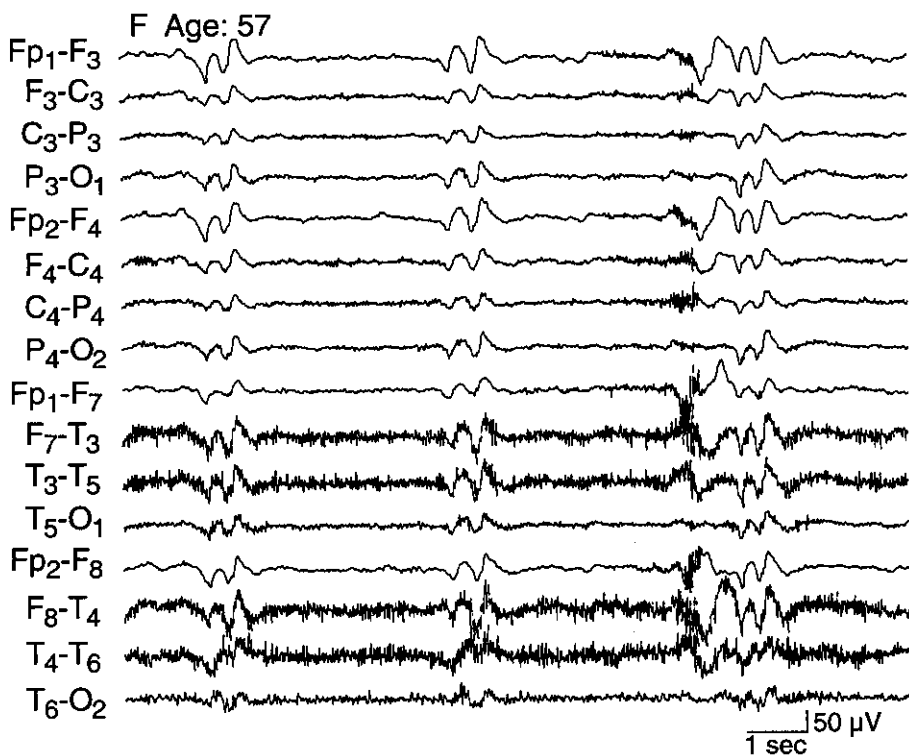


FIG. 16. Periodic glossokinetic potentials.

Intraoral

The tongue, like the eyeball, has a direct current (DC) potential that is evident in standard EEG recording only when the tongue is moved. We called the resultant artifacts "glossokinetic potentials" (Klass and Bickford 1960). For reasons that have not yet been fully explained, some people have very prominent glossokinetic potentials (Westmoreland et al. 1973, Blume and Kaibara 1995), and these potentials may obscure the cerebral activity in an EEG recording (Figure 14). These artifacts are most prominent in the temporofrontal leads and are least prominent at the vertex. Glossokinetic potentials may resemble frontal intermittent rhythmic delta activity (FIRDA) (Figure 15), periodic bursts of diffuse slow waves (Figure 16), or electrographic seizure discharges (Figure 17). Glossokinetic potentials can be monitored by close observation of the patient or by recording with electrodes on the cheeks. If artifacts are suspected of being glossokinetic potentials, it is helpful to compare the waveform and topography of

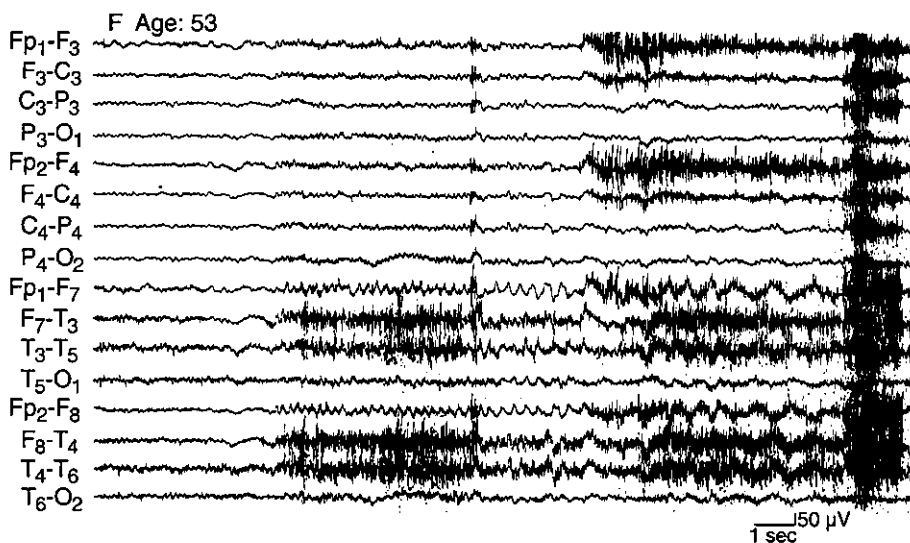


FIG. 17. Evolving frequency of glossokinetic potentials due to lateral tongue movement (lower eight channels) resembles a subclinical electrographic seizure discharge.

the activity in question with glossokinetic potentials voluntarily induced by having the patient say a word with lingual consonants, such as "lilt."

An artifact first described by a technologist (Milnarich et al. 1957) is the sharp discharge arising from dissimilar metals within the mouth (Figure 18). It closely resembles an electrostatic discharge from a technologic or extrinsic source. Like the glossokinetic potentials, this artifact is most prominent in the temporal and frontal leads. It can be reduced by having the patient keep the mouth open. A typical triad of artifacts identifies the act of swallowing when the patient exhibits a conjunction of dissimilar metal artifact, glossokinetic potential, and temporal muscle activity (Figure 19).

Electrodermal

In the early days of EEG before the prevalence of air conditioning, sweating was a major problem because of the continuous slow potentials it produced. Sweating, which can affect all areas of the scalp and especially the forehead, can still be a problem in recording from patients with febrile illnesses or in the typically warm environment of the intensive care unit (ICU). In these circumstances, the technologist should avoid using an electrode placement system em-

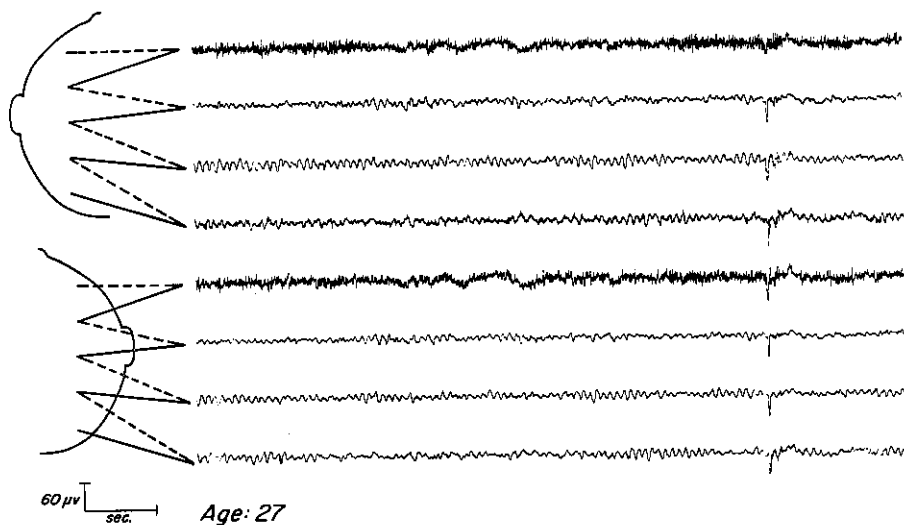

FIG. 18. Sharp potentials from dissimilar metals in the teeth.

bedded in a tightly fitting elastic cap. A portable fan, compressed air, and anti-perspirant spray can help reduce artifacts from sweating.

Intermittent slow waves, typically biphasic, can occur from electrodermal potentials in anxious patients without gross sweating (Picton and Hillyard 1972). This activity, also known as the galvanic skin reflex (GSR), can resemble slow waves of cerebral origin, but the electrodermal potentials do not have the field distribution of cerebral slow waves, glossokinetic potentials, or eye movement artifacts (Figure 20). The GSR can be identified by purposely inducing it with a sudden stimulus such as a handclap and recording a similar response after a suitable latency in leads on the palm and dorsum of the hand (Yokota et al. 1959). To reduce the GSR, attempts should be made to relax the patient and avoid any anxiety-provoking maneuvers. The electrodermal potentials are not recorded with subdermal needle electrodes.

Cephalic and Corporeal Movement

Head movement may produce an artifact that closely resembles cerebral EEG activity and that is particularly prone to occur in an electrode or electrodes pressing against a reclining chair or bed (Figure 21). It is imperative for the technician to note the patient's head position at the time the suspected artifact

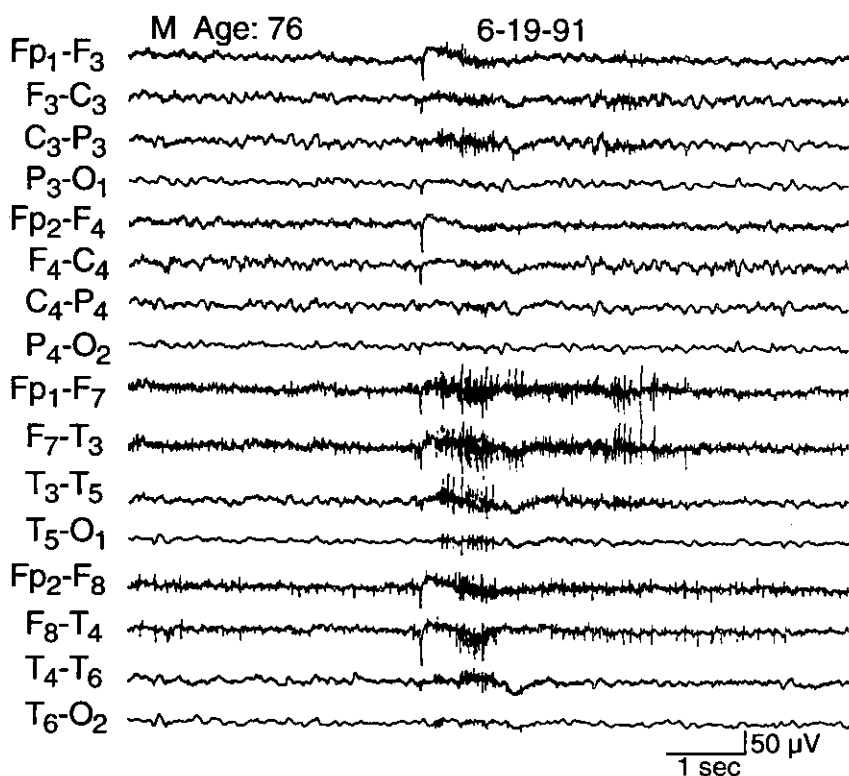


FIG. 19. Triad of artifacts with swallowing. The initial spike-like discharge is due to dissimilar metals in the teeth and is followed by glossokinetic and myogenic potentials.

occurs and, if the patient is awake, to eliminate the artifact by propping the patient's head away from the chair or bed or to verify the artifact by changing the head position and noting the resultant change in distribution of the artifact in the recording.

Patients with a hand tremor may induce a rhythmic artifact by eyelid movement when asked to hold the eyelids closed to reduce an excessive eye movement artifact. Patients with a resting head tremor due to parkinsonism often have a characteristic artifact consisting of rhythmic 4-7 Hz waves in the occipital leads associated with myogenic potentials at the same frequency (Westmoreland et al. 1973). Simultaneous monitoring with an accelerometer establishes the extracerebral origin of the activity. In patients with involuntary movements of an extremity, surface electromyographic leads to monitor the movements help determine whether a related cerebral event is present in the scalp-recorded EEG.

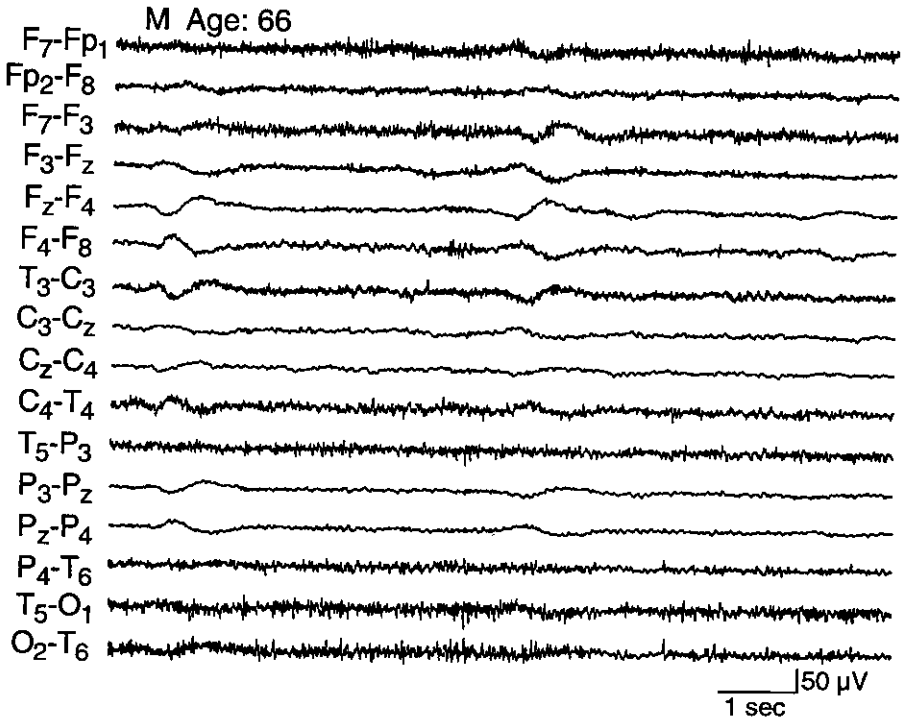


FIG. 20. Slow waves due to electrodermal potentials most prominent anteriorly.

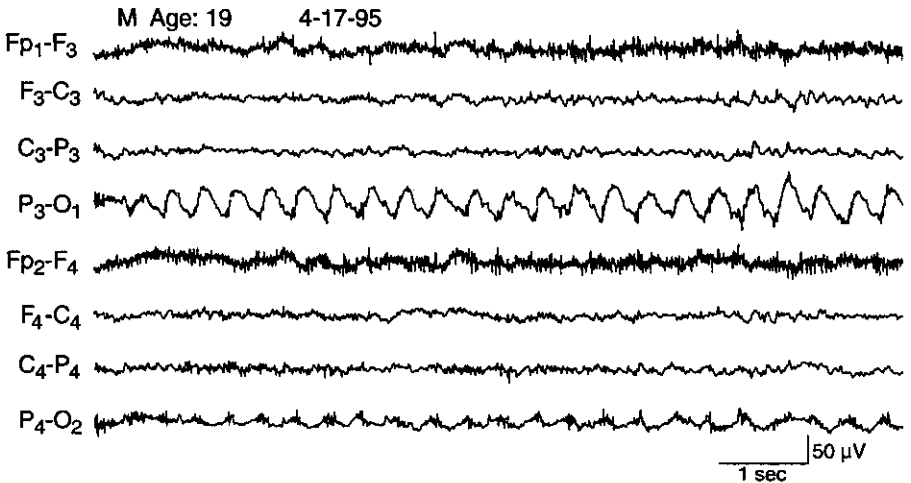


FIG. 21. Rhythmic head movement affecting the occipital leads, maximal in O1 and resembling focal rhythmic delta activity. The patient was lying supine with his head turned slightly to the left.

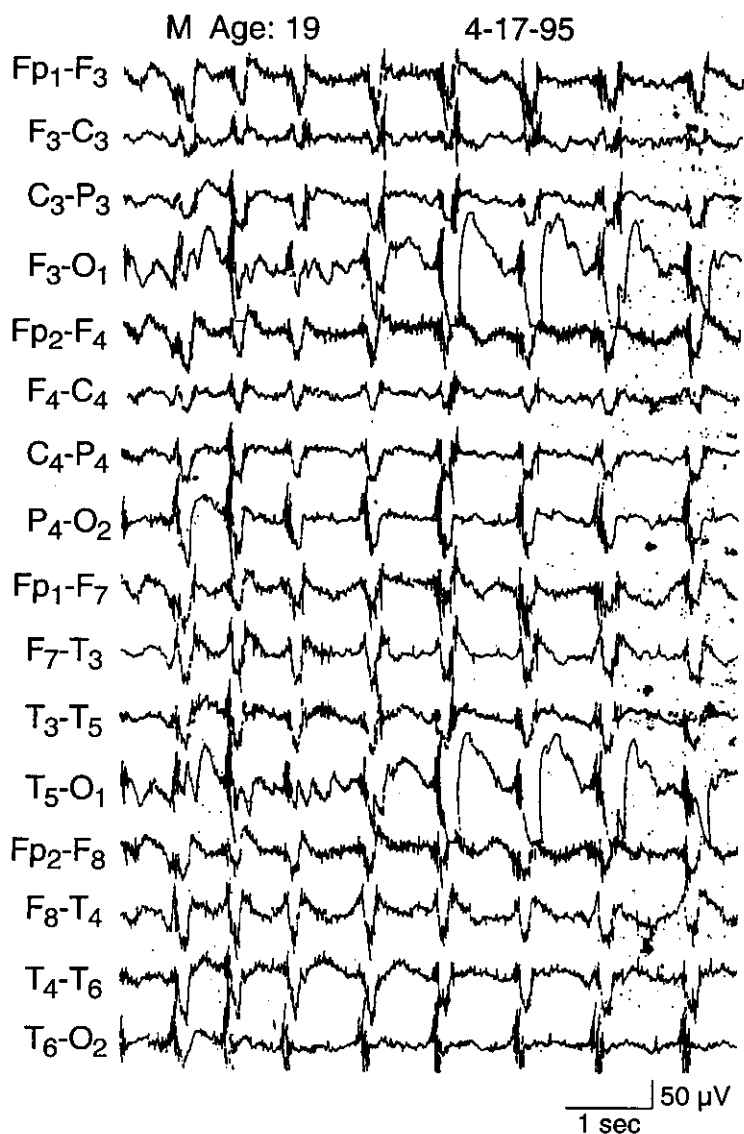


FIG. 22. Artifacts from periodic nonepileptic tics resembling paroxysmal EEG abnormalities.

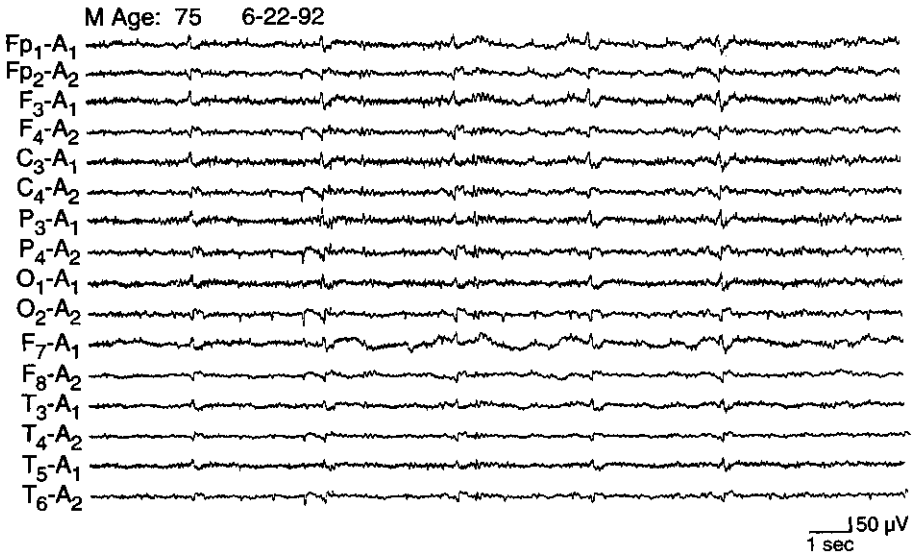


FIG. 23. Periodic electrocardiographic artifacts due to premature ventricular contractions.

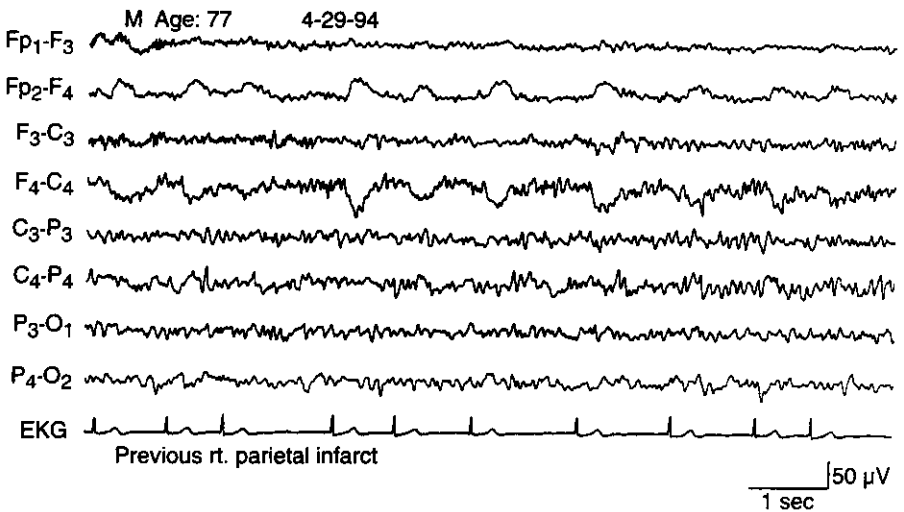


FIG. 24. Irregular pulse artifact (F4) due to cardiac arrhythmia, to be differentiated from focal polymorphic delta activity in P4 related to previous right parietal infarct. The electrocardiogram is monitored in lowermost channel (labeled EKG).




FIG. 25. Rhythmic artifact from shaking input cable. No electrodes from the patient were plugged into the input jack box. Electrode selector switches were set for the intended montage.

Chewing movements and nonepileptic tics may induce artifacts resembling periodic abnormal EEG activity (Figure 22).

Cardiovascular

Patients with known or unsuspected cardiac disease may be referred to the EEG laboratory for a variety of symptoms, including episodes of loss of consciousness that may or may not be epileptic seizures. Simultaneous use of an ECG monitor with a lead on the clavicle or wrist throughout the recording is important for identifying cardiogenic artifacts in the EEG that may resemble abnormal spikes or sharp waves (Figure 23) or bursts of rhythmic slow waves (Sams 1970). ECG monitoring has proven to be useful for capturing cardiac abnormalities that may be responsible for the patient's symptoms, such as bradycardia, paroxysmal tachycardia, episodic asystole (Espinosa et al. 1978), and prolonged QT intervals (Gospe and Gabor 1990).

An ECG monitor is also useful for identifying pulse artifacts in scalp leads (Blume and Kaibara 1995) and is particularly important if the heart rate is irregular and the pulse artifact more closely resembles focal polymorphic delta activity (Figure 24). With separately applied "stick-on" electrodes, a pulse artifact rarely affects more than one lead at the same time, but a pulse artifact in more

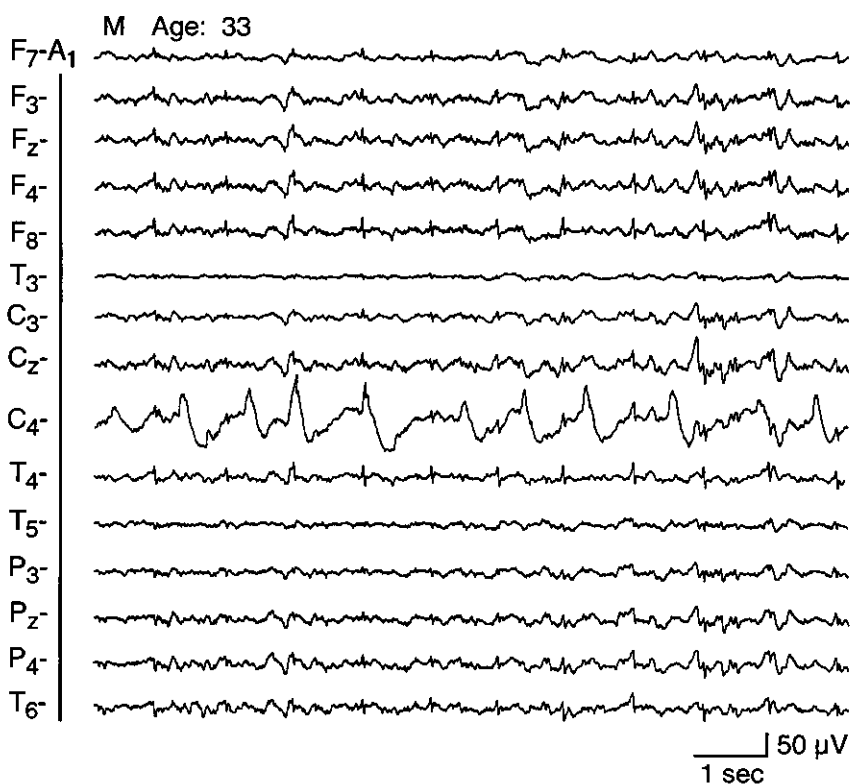


FIG. 26. Rhythmic sharp waves due to electrode artifact (C4). Periodic electrocardiographic artifact is also evident in all channels in this referential recording to A1.

than one lead is encountered fairly frequently when the electrodes are embedded in a tightly fitting elastic cap of the type originally designed by Frost (1971, 1973) for use by astronauts or in elastic bands or pods. The mechanism is slight pressure of the electrodes on underlying scalp arteries.

Physiologic artifacts in neonatal recordings have been described by Stockard-Pope et al. (1992) and by Scher (1985), and the abundant physiologic artifacts encountered in ambulatory cassette recording can closely resemble abnormal EEG activity (Ebersole et al. 1983, Jayakar et al. 1985).

TECHNOLOGIC ARTIFACTS

Artifacts may arise anywhere in the system connecting the patient to the EEG instrument, including the electrode-scalp interface, the electrode, the lead,

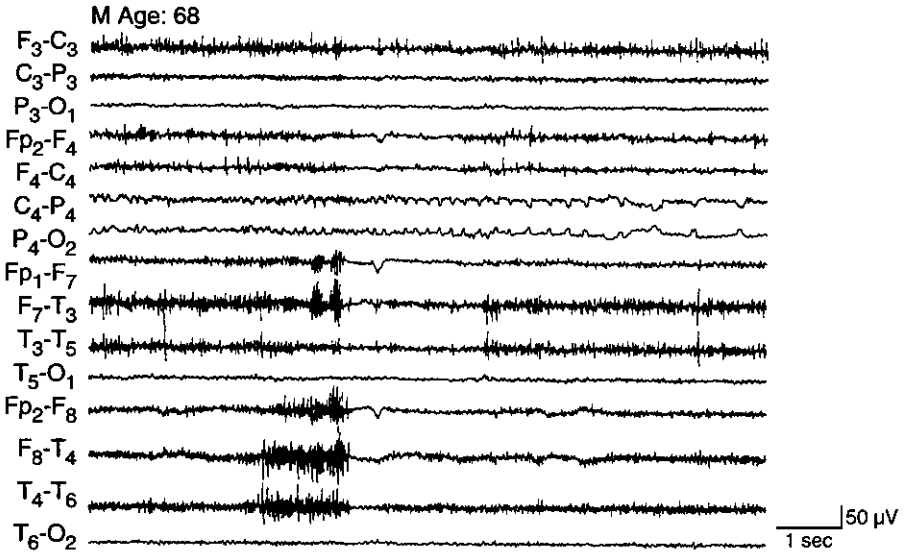


FIG. 27. Evolving frequency and voltage of electrode artifact (P4) resembling a focal electrographic seizure discharge.

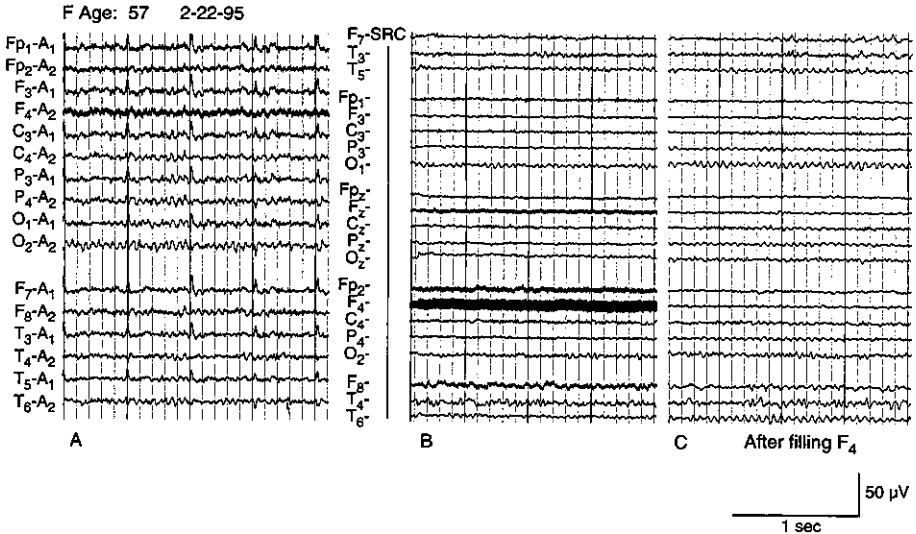


FIG. 28. High-impedance electrode contact (F4) introducing 60-Hz artifact. The artifact is clearly confined to F4 in referential montage (segment A). The artifact is maximal in F4 but also appears to involve Fp2, Fz, and F8 in Laplacian montage (segment B). It disappears from all four leads after the contact paste is refilled in F4 only (segment C). SRC, "source derivation" consisting of the neighboring leads for each electrode in segments B and C.

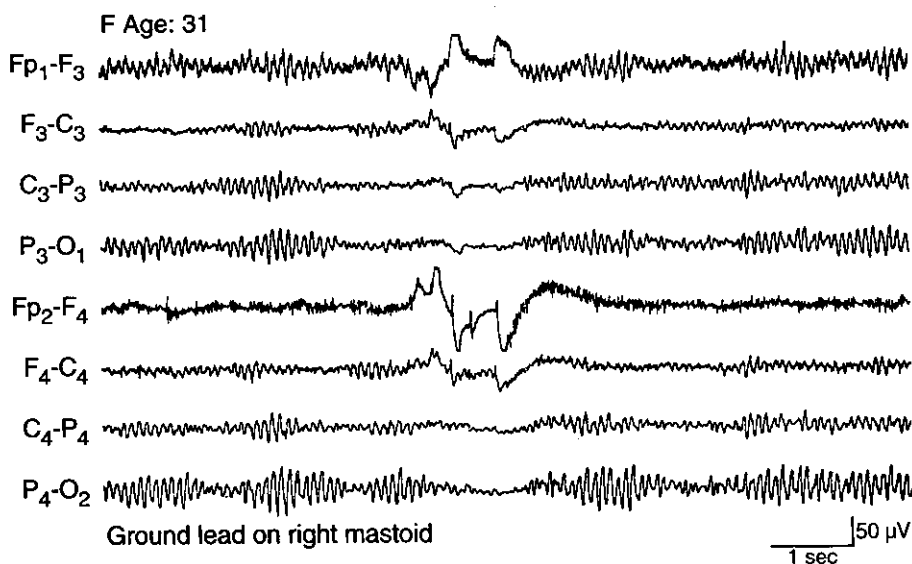


FIG. 29. Defective electrode (Fp1) allowing the ground lead on the right mastoid to act as a recording lead for input 1 of channel 1. As a result, the alpha rhythm is introduced into channel 1, and the eye movement artifacts in that channel are reversed in direction.

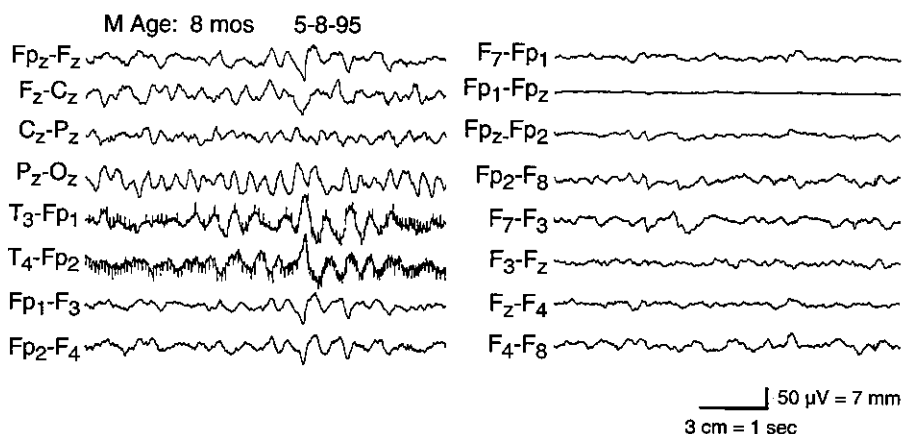


FIG. 30. Overflow of contact paste between electrodes Fp1 and Fp2 is not apparent when these electrodes are each connected to other leads (segment on left) but produces a flattened tracing (channel 2 in segment on right) when Fp1 and Fp2 are interconnected.

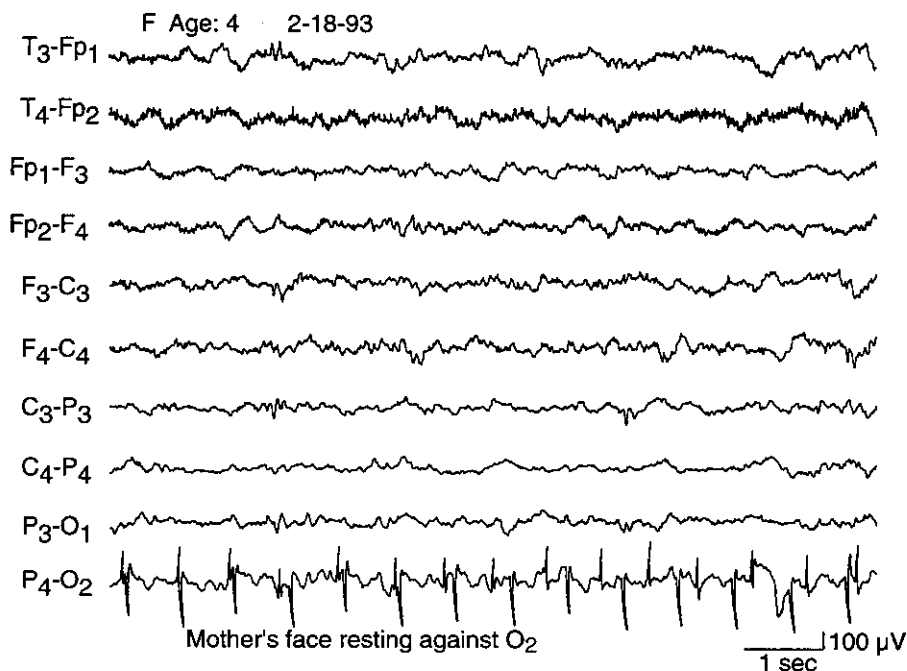


FIG. 31. Dual electrocardiographic artifacts in recording of child (faster rate) being held by her mother (slower rate), recorded in lowermost channel because of salt bridge from sweat. The left side of the mother's face was in contact with O₂. The spikes in C3-P3 are of cerebral origin.

the jack plug, the jack-box receptacle, and the input cable. Electrode-scalp impedance should be tested before every recording. The integrity of the system can easily be verified by lightly touching each electrode and determining if the induced artifact corresponds to the appropriate electrode position in the recorded EEG. This procedure is essential when recording for suspected electrocerebral inactivity, since extrinsic artifacts can resemble cerebral activity (Figure 25).

Although an electrode artifact is often considered to have the typical appearance of a sporadic, abrupt deflection, commonly called an electrode "pop," electrode artifacts can be manifested by rhythmic activity of various frequencies (Figure 26) or even take the form of a discharge with evolving frequency resembling an electrographic seizure discharge (Figure 27). With standard analog recording, however, the artifactual discharge does not spread to involve adjacent leads, even when the artifact achieves a considerable voltage. This principle, however, does not hold true in digital recording using the source derivation (Laplacian) system (Hjorth 1980). In that system, each lead is referred to a

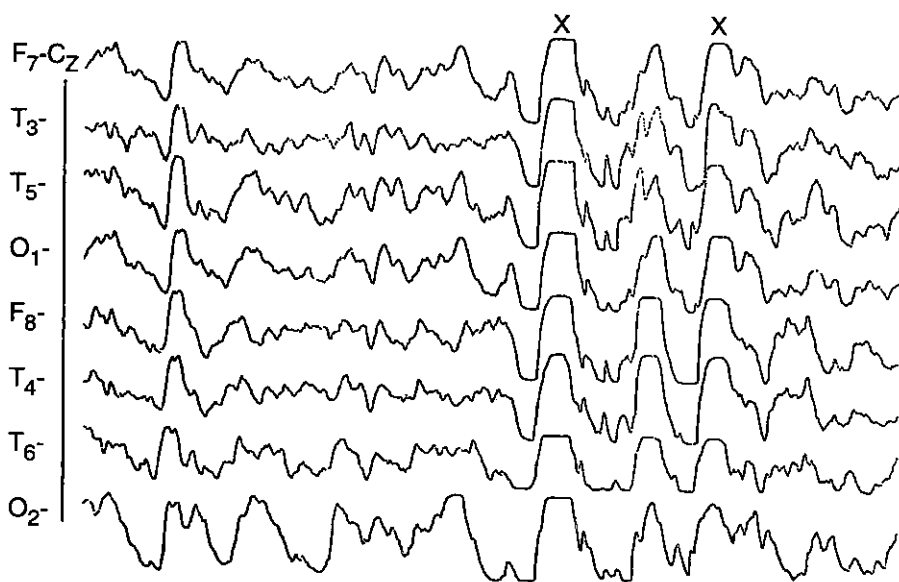


FIG. 32. Artifacts in EEG due to tremors (X) of California earthquake. (Courtesy of Dr. James C. White.)

combination of the surrounding leads, one of which may be the electrode producing the artifact (Figure 28). Recognition of this fact enables the technologist to attend to the appropriate defective electrode as the source of the artifact rather than to fruitlessly search for an extrinsic source that seemingly affects multiple leads.

It is imperative for the technologist to indicate the location of the patient ground lead, since a defective, high-impedance, or even disconnected electrode permits the ground lead to act as a recording lead in its place. The pattern of recorded activity is recognizably different if, for example, the ground lead is in the midfrontal region or is located on a mastoid prominence (Figure 29). If the EEG instrument has a high in-phase rejection ratio, intrusion of a 60 Hz artifact may not occur even when one lead is completely disconnected from the patient.

As mentioned previously, use of the high-frequency filter should be avoided during sleep, since an otherwise clear-cut electrode "pop" may be blunted and more closely resemble an EEG sharp wave. Instrumental artifacts are extremely varied, and their recognition depends on familiarity with the particular equipment being used (Cooper et al. 1969, Saunders 1979, Tyner et al. 1983, Brittenham 1990).

A salt bridge due to overflow of electrode contact paste between two elec-

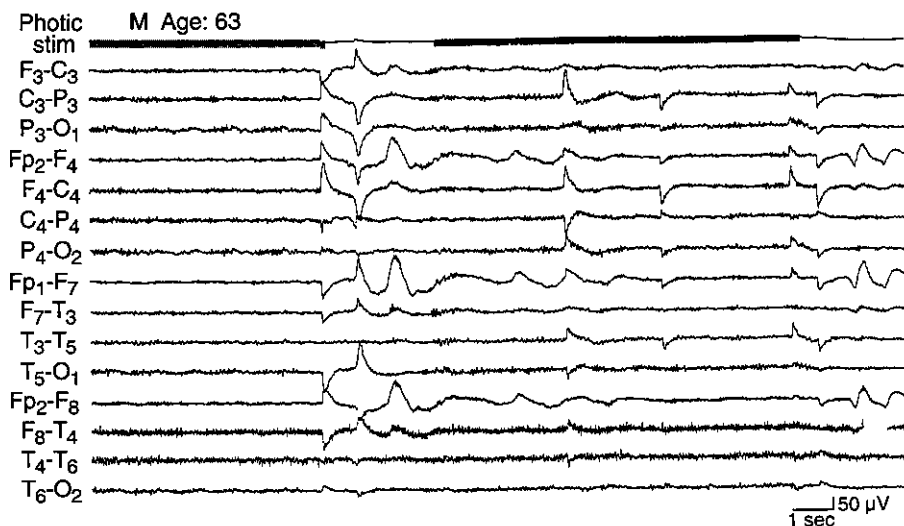


FIG. 33. Abrupt sharp deflections due to use of a nearby walkie-talkie and unrelated to the photic stimulation being performed at the time (stimulus marker in channel 1).

trodes is rarely encountered with separately applied electrodes in the standard 10-20 placement system but may occur with more closely spaced electrodes (American Electroencephalographic Society 1994) or with electrodes embedded in an elastic cap (Figure 30). A salt bridge from sweat can produce an unusual appearance of two separate ECGs in the same patient, as when a perspiring mother and child are in contact with each other (Figure 31).

EXTRINSIC ARTIFACTS

Innumerable artifacts can arise from environmental sources. Some aberrations of nature may be readily apparent, such as the tremors of an earthquake (Figure 32), whereas others, such as lightning (Jacome and Risko 1986), may not be apparent in a windowless EEG laboratory.

Use of a nearby radio frequency walkie-talkie as the source of an artifact is usually identifiable (Figure 33); however, as Silbert et al. (1994) recently reported, cellular telephones can induce artifacts when they are turned on but not actually being used, and many are small enough to be concealed. Prolific and diverse artifacts occur when EEGs are recorded in the ICU, at the patient's bedside (Bennett et al. 1976), or in the operating room (Hanley and Charlton 1982). Unplugging unnecessary equipment and use of the 60 Hz notch filter are first steps in reducing 60 Hz interference. Sometimes the attending physician will

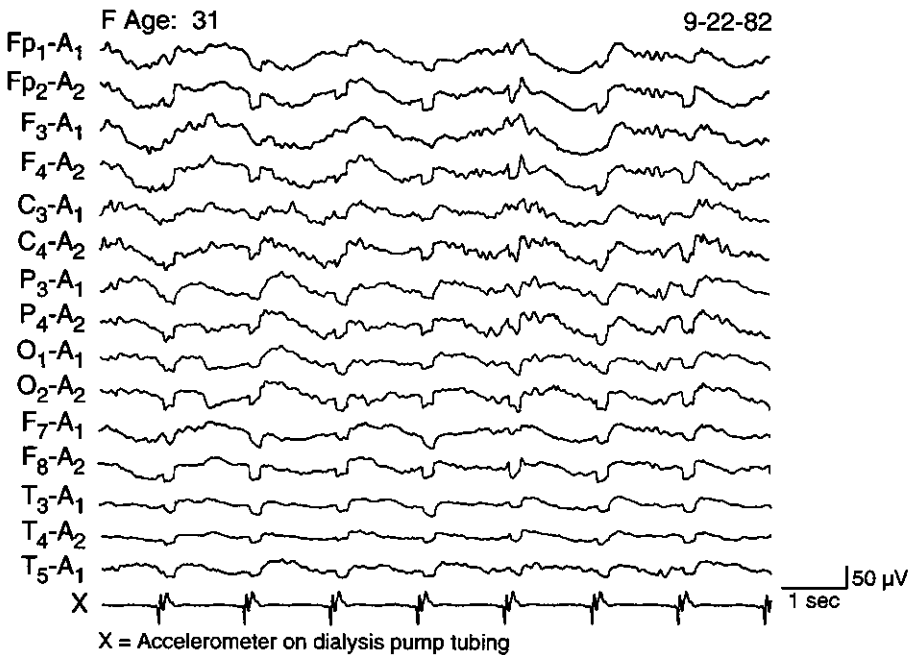


FIG. 34. Periodic artifacts in all channels of EEG recorded during renal dialysis. Each artifact coincides with the deflections of an accelerometer on the dialysis pump tubing (lowermost channel).

permit temporary interruption of the offending equipment to verify the source of the artifact and enable the technologist to obtain at least a segment of artifact-free recording. The technologist should monitor recurring artifacts and mark in the recording when they occur, so that artifacts from an intravenous drip (Saunders 1979), an infusion motor (Lininger et al. 1981), or a dialysis pump (Figure 34) will not be misconstrued as periodic spikes, and periodic rhythmic artifacts from a respirator or respiratory-related secretions will not be mistakenly viewed as a cerebral burst-suppression pattern (Sims et al. 1973, Bennett et al. 1976, Sahota et al. 1993). Recordings in the ICU frequently contain a combination of biologic, technologic, and extrinsic artifacts (Figure 35); nevertheless, EEG has an important place in assessing cerebral function in patients who are immobilized or are too seriously ill to be transported for tests such as neuroimaging procedures. I have been impressed by the observation that well-trained and experienced technologists can obtain interpretable recordings so frequently under such adverse environmental circumstances.

As pointed out by Gloor (1969), at the very inception of EEG, Hans Berger




FIG. 35. Combination of artifacts in EEG being recorded in the intensive care unit, including bursts of rhythmic activity from the respirator (all channels), irregular deflections from bedside computer (mainly in channels 3 and 4), electrocardiographic artifact (all channels), and probable electrode artifact (T6).

took great care to demonstrate that the electrical current oscillations he recorded were arising from the brain and could not be attributed to "cerebral pulsations, to the cerebral blood flow, to the electrocardiogram, to blood flow through scalp vessels, to skeletal or smooth muscle artefact, to eye movements, or to the electrical properties of the skin." Technological advances in EEG since 1929 notwithstanding, artifacts continue to be challenging.

ACKNOWLEDGMENT

The author is grateful to Mrs. Jeanette Connaughty for her invaluable work in processing the manuscript and illustrations.

Address reprint requests to Donald W. Klass, M.D., Mayo Clinic, 200 First Street SW, Rochester, MN 55905, USA.

REFERENCES

- American Electroencephalographic Society (1994): Guideline thirteen: Guidelines for standard electrode position nomenclature. *J. Clin. Neurophysiol.*, 11:111-13.
- Barlow, J. S. (1986): Artifact processing (rejection and minimization) in EEG data processing.

- In: Lopes da Silva, F. H., van Leeuwen, S., and Remond, A. (Eds.), *Handbook of Electroencephalography and Clinical Neurophysiology*. (Revised series) (Vol. 2. Clinical Applications of Computer Analysis of EEG and Other Neurophysiological Signals). Elsevier Scientific Publishing Company, Amsterdam, pp. 15-62.
- Bennett, D. R., Hughes, J. R., Korein, J., Merlis, J. K., and Suter, C. (1976): *Atlas of Electroencephalography in Coma and Cerebral Death: EEG at the Bedside or in the Intensive Care Unit*. Raven Press, New York, 244 pp.
- Blume, W. T., and Kaibara, M. (1995): *Atlas of Adult Electroencephalography*. Raven Press, New York, 569 pp.
- Brittenham, D. (1974): Recognition and reduction of physiological artifacts. *Am. J. EEG Technol.*, 14:158-65.
- Brittenham, D. M. (1990): Artifacts. Activities not arising from the brain. In: Daly, D. D., and Pedley, T. A. (Eds.), *Current Practice of Clinical Electroencephalography*. 2nd ed. Raven Press, New York, pp. 85-105.
- Coburn, K. L., and Moreno, M. A. (1988): Facts and artifacts in brain electrical activity mapping. *Brain Topogr.*, 1:37-45.
- Cooper, R., Osselton, J. W., and Shaw, J. C. (1969): *EEG Technology*. Butterworth, London, 186 pp.
- Dondey, M., and Gaches, J. (Eds.) (1977): Artefacts. In: Rémond, A. (Ed.-in-Chief), *Handbook of Electroencephalography and Clinical Neurophysiology* (Vol. 11. Part A: Semiology in Clinical EEG). Elsevier Scientific Publishing Company, Amsterdam, pp. 80-96.
- Ebersole, J. S., Bridgers, S. L., and Silva, C. G. (1983): Differentiation of epileptiform abnormalities from normal transients and artifacts on ambulatory cassette EEG. *Am. J. EEG Technol.*, 23:113-25.
- Espinosa, R. E., Klass, D. W., and Maloney, J. D. (1978): Contribution of the electroencephalogram in monitoring cardiac dysrhythmias. *Mayo Clin. Proc.*, 53:119-22.
- Espinosa, R. E., Lambert, E. H., and Klass, D. W. (1967): Facial myokymia affecting the electroencephalogram. *Mayo Clin. Proc.*, 42:258-70.
- Fisch, B. J. (1991): *Spehlmann's EEG Primer*. 2nd revised ed. Elsevier Science Publishing Company, Amsterdam, 634 pp.
- Franklin, S. (1972): Problem record of the month. *Am. J. EEG Technol.*, 12:141-42.
- Frost, J. D., Jr. (1971): Portion of final report. *Contract NAS 9-10747*, pp. 2-25.
- Frost, J. D., Jr. (1973): Final report. *Contract NAS 9-12460*, pp. 1-29.
- Gloor, P. (Ed.) (1969): Hans Berger on the electroencephalogram of man. *Electroencephalogr. Clin. Neurophysiol. Suppl.* 28:1-350.
- Gospe, S. M., Jr., and Gabor, A. J. (1990): Electroencephalography laboratory diagnosis of prolonged QT interval. *Ann. Neurol.*, 28:387-90.
- Hanley, J. A., and Charlton, M. H. (1982): EEG in the operating room: Artifacts and unusual waveforms. *Am. J. EEG Technol.*, 22:135-41.
- Hertzler, J. J., Goldstein, N. P., and Klass, D. W. (1970): Electroencephalogram in patients with palatal myoclonus. *Electroencephalogr. Clin. Neurophysiol.*, 28:90.
- Hjorth, B. (1980): Source derivation simplifies topographical EEG interpretation. *Am. J. EEG Technol.*, 20:121-32.
- Jacome, D. E., and Risko, M. (1986): Lightning artifact in the EEG. *Clin. Electroencephalogr.*, 17:105-9.
- Jayakar, P. B., Patrick, J. P., Sill, J., Shwedyk, E., and Seshia, S. S. (1985): Artifacts in ambulatory cassette electroencephalograms. *Electroencephalogr. Clin. Neurophysiol.*, 61: 440-43.
- Jordan, J. E., Grice, S. T., Mikiten, T. M., and Ferber, G. (1977): The EEG in palatal myoclonus—an unusual artifact. *Clin. Electroencephalogr.* 8:141-49.
- Keeney, S. (1981): Artifact: Sources and solutions. *Am. J. EEG Technol.*, 21:147-58.
- Klass, D., and Bickford, R. G. (1960): Glossokinetic potentials appearing in the electroencephalogram (abstract). *Electroencephalogr. Clin. Neurophysiol.*, 12:239.
- Lininger, A. W., Volow, M. R., and Gianturco, D. T. (1981): Intravenous infusion motor artifact. *Am. J. EEG Technol.*, 21:167-73.

- MacGillivray, B. B. (Ed.) (1974): Artefacts, faults and fault-finding. In: Rémond, A. (Ed.-in-Chief), *Handbook of Electroencephalography and Clinical Neurophysiology* (Vol. 3. Part C: Traditional Methods of Examination in Clinical EEG). Elsevier Scientific Publishing Company, Amsterdam, pp. 88-102.
- Matsuo, F., and Gaskin, J. A. (1986): Unexpected REM sleep episodes in standard EEG laboratory recording. *Am. J. EEG Technol.*, 26:33-40.
- Milnarich, R. F., Tourney, G., and Beckett, P. G. S. (1957): Electroencephalographic artifact arising from dental restorations. *Electroencephalogr. Clin. Neurophysiol.*, 9:337-39.
- Mraz, V., and Sullivan, N. H. (1994): Quantitative EEG: The confounding effects of eye movement. *Am. J. EEG Technol.*, 34:177-84.
- Nuwer, M. R. (1988): Quantitative EEG: I. Techniques and problems of frequency analysis and topographic mapping. *J. Clin. Neurophysiol.*, 5:1-43.
- Nuwer, M. R., and Jordan, S. E. (1987): The centrifugal effect and other spatial artifacts of topographic EEG mapping. *J. Clin. Neurophysiol.*, 4:321-26.
- Picton, T. W., and Hillyard, S. A. (1972): Cephalic skin potentials in electroencephalography. *Electroencephalogr. Clin. Neurophysiol.*, 33:419-24.
- Radhakrishnan, K., Silbert, P. L., and Klass, D. W. (1994): Breach activity related to an osteolytic skull metastasis. *Am. J. EEG Technol.*, 34:1-5.
- Sahota, P. K., Bray, F., and Garcia-Mendez, L. (1993): Respiration-related artifact presenting as intermittent rhythmic theta activity. *Am. J. EEG Technol.*, 33:121-28.
- Sams, M. W. (1970): Problem record of the month. No. 1, part 2. *Am. J. EEG Technol.*, 10: 65-68.
- Saunders, M. G. (1979): Artifacts: Activity of noncerebral origin in the EEG. In: Klass, D. W., and Daly, D. D. (Eds.), *Current Practice of Clinical Electroencephalography*. Raven Press, New York, pp. 37-67.
- Scher, M. S. (1985): Physiologic artifacts in neonatal electroencephalography: The importance of technical comments. *Am. J. EEG Technol.*, 25:257-77.
- Shaffer, M. A. (1970): Problem record of the month. No. 3: Asymmetrical eye-blink artifact. *Am. J. EEG Technol.*, 10:153-56.
- Silbert, P. L., Roth, P. A., Kanz, B. S., Radhakrishnan, K., and Klass, D. W. (1994): Interference from cellular telephones in the electroencephalogram. *Am. J. EEG Technol.*, 34:6-12.
- Sims, J. K., Aung, M. H., Bickford, R. G., Billinger, T. W., and Shattuck, C. M. (1973): Respirator artifact mimicking burst-suppression during electrocerebral silence. *Am. J. EEG Technol.*, 13:81-87.
- Stockard-Pope, J. E., Werner, S. S., and Bickford, R. G. (1992): *Atlas of Neonatal Electroencephalography*. 2nd ed. Raven Press, New York, 401 pp.
- Sullivan, L. R. (1993): Technical tips: Eye movement monitoring. *Am. J. EEG Technol.*, 33: 135-47.
- Tyner, F. S., Knott, J. R., and Mayer, W. B., Jr. (1983): *Fundamentals of EEG Technology*. Vol. 1: Basic Concepts and Methods. Raven Press, New York, 320 pp.
- Westmoreland, B. F., Espinosa, R. E., and Klass, D. W. (1973): Significant prosopo-glossopharyngeal movements affecting the electroencephalogram. *Am. J. EEG Technol.*, 13:59-70.
- Williams, G. W., Luders, H. O., Brickner, A., Goormastic, M., and Klass, D. W. (1985): Interobserver variability in EEG interpretation. *Neurology* 35:1714-19.
- Yokota, T., Takahashi, T., Kondo, M., and Fujimori, B. (1959): Studies on the diphasic wave form of the galvanic skin reflex. *Electroencephalogr. Clin. Neurophysiol.*, 11:687-96.